

This article is licensed under the Creative Commons Attribution-NonCommercial 4.0 International License (CC BY-NC) (<http://www.karger.com/Services/OpenAccessLicense>). Usage and distribution for commercial purposes requires written permission.

Case Report

Optic Neuropathy due to an Ethmoid Mucocele: A Case Report and Literature Review

Magdalene Yin Lin Ting^{a, b} Meghan Shan^b Oliver Gantz^c
Sandy Zhang-Nunes^b Bozena Wrobel^c

^aUniversity of Cambridge School of Clinical Medicine, Cambridge, UK; ^bDepartment of Oculoplastics, Keck Medicine of USC, Los Angeles, CA, USA; ^cUSC Caruso Department of Otolaryngology – Head and Neck Surgery, Los Angeles, CA, USA

Keywords

Optic nerve · Neuropathy · Ethmoid sinus · Mucocele

Abstract

Mucoceles of the paranasal sinus commonly involve the frontal sinuses, the ethmoid sinuses, and rarely the maxillary or sphenoid sinuses. They often present with sinus pain or pressure, but rarely can present with more severe symptoms such as changes in mental status or vision due to expansion and invasion through the skull base or orbit. A 62-year-old male presented with optic neuropathy, a relative afferent pupillary defect with proptosis and lateral gaze palsy of the left eye. The patient was found to have a large mucocele extending from the left posterior ethmoid sinus into the left orbital apex. Urgent endoscopic sinus surgery was performed jointly between Oculoplastics and Otolaryngology. Post-operatively, the patient had improvement in diplopia, extraocular motion, and proptosis with stable vision. This case demonstrates the importance of early identification and intervention in a rare presentation of a sinus mucocele to prevent serious complications such as vision loss.

© 2019 The Author(s)
Published by S. Karger AG, Basel

Introduction

Sinus mucoceles are benign cystic lesions that occur most commonly in the frontal sinuses, and rarely the posterior ethmoid and sphenoid sinuses. It is thought that mucoceles develop due to accumulated secretions in the sinus caused by an obstructed ostium. Although benign lesions, mucoceles can be locally destructive as they expand. Patients commonly present with symptoms of headache, facial pressure or swelling, nasal obstruction, and nasal discharge. They can also present with ophthalmic manifestations such as proptosis, periorbital pain, restricted ocular mobility, and vision changes such as diplopia, blurred vision, or loss of vision. We present a case of a patient who developed evidence of optic nerve compression due to a large posterior ethmoid mucocele.

Case Report

A 62-year-old male with a past medical history remarkable only for hypertension first presented in May 2016 to his primary care physician with left-sided progressively worsening vision associated with discomfort, diplopia worse on right gaze, epiphora, and clear discharge that had developed over the past year. On examination, he had limited extraocular movement in the left eye and was subsequently referred to an optometrist and ophthalmologist. An MRI was performed with evidence of sinus disease, including a likely mucocele (Fig. 1). He was referred to Otolaryngology for further evaluation and management.

Endoscopic sinus surgery was discussed and Oculoplastic Surgery was consulted given evidence of orbital invasion on imaging. When the patient was first seen in the Oculoplastic Clinic his vision had declined further to 20/400 (20/300 on pinhole) and there was demonstration of optic neuropathy and relative afferent pupillary defect (RAPD), likely from optic nerve compression by the sinus mucocele, with possible infection. On examination, he exhibited unilateral proptosis and lateral gaze palsy of the left eye (Fig. 2). Dilated fundus examination was notable only for venous tortuosity in the left eye.

Given concern for worsening optic neuropathy in the setting of an enlarging ethmoid mucocele with possible super-infection, the patient was admitted for IV steroids and antibiotics, and scheduled for urgent endoscopic drainage. The patient underwent endoscopic sinus surgery with bilateral total ethmoidectomy, mucocele excision, and removal of the compressive effects on the optic nerve on the left without any noted complications.

Histological and immunohistochemical testing noted minimal eosinophils and no fungal organisms, malignancy, or papilloma in any parts of the samples sent. Both the mucocele wall and left sinus samples were significant for bone and fibrotic tissue with focal old haemorrhage, whilst the left sinus sample also showed reactive-appearing histiocyte aggregates.

Post-operatively, his vision was 20/25–2 with persisting RAPD. His vision and motility had significantly improved (Fig. 3). There was significant proptosis reduction, with slight ptosis from the resulting enophthalmos. A month later, there was residual mucus discharge from the left nasal cavity. On nasal endoscopy there was expected post-surgical crusting in the ethmoid area. The patient was recommended to continue daily sinus rinses.

Discussion/Conclusion

Paranasal sinus mucoceles typically occur in the third to fourth decades of life, with a mild male predisposition [1, 2]. The aetiology of mucocele formation is multifactorial [3]. Commonly, the obstruction of sinus ostium ventilation is the principle cause. This can be due to inflammation, allergy, trauma, mass lesions, or others such as iatrogenic or idiopathic causes [4, 5]. When outflow is obstructed, mucous secretions from the pseudostratified ciliated columnar epithelium lining the sinuses accumulate within the normally air-filled sinuses, resulting in these benign cysts [6]. Immunologically, mucoceles are shown to have elevated expression of IL-12 and secondary increases in expressions of IL-2 and IFN- γ . This consequently causes activation of TH2 lymphocytes which hasten chronic inflammation [2].

Pressure build-up then leads to gradual distension, thinning, and erosion of the walls of the sinus. Typically, mucoceles are found to involve the frontal sinuses most commonly (65%), followed by the ethmoidal sinuses (30%), and rarely the maxillary or sphenoid sinuses (1–10%) [7, 8]. Over time, the expanding mucocele can invade the orbit, nasopharynx, or cranium depending on anatomical site. Symptoms depend on site. Generally, these are categorized as ophthalmological, rhinological, or neurological [1]. For example, fronto-ethmoidal mucoceles tend to cause mass effect on the ipsilateral orbit, resulting in proptosis, diplopia, and possible periorbital swelling, whereas posterior ethmoid and sphenoid mucoceles more commonly lead to optic canal compression and cause visual symptoms [9].

Early identification and intervention are crucial in preventing visual compromise or spreading infection. Diagnosis can be made through a combination of physical examination and radiographic studies including CT and MRI. Diplopia, proptosis, tearing, and evidence of a periorbital mass on imaging is a presentation commonly reported in patients with a frontal or ethmoidal mucocele extending into the orbit. Loss of vision occurs less commonly, and our literature review shows 93 of 457 mucoceles (20.35%) present with visual disturbance (Table 1).

CT provides anatomical detail and bony delineation which is helpful in surgical planning. MRI is superior to CT in demonstrating the relationship between the mucocele and adjacent soft tissue, as well as differentiating mucoceles from other soft tissue neoplasms [9].

Surgical excision is the treatment of choice and necessary to prevent recurrence [10, 11]. Previously, this was done via external approaches but current trends move towards endoscopic management. The reported recurrence rate for mucoceles following endoscopic management remains low [12] and has been shown to be lower than recurrence rates for external approaches [7]. When performed appropriately, it has been shown to improve morbidity and recurrence rates as demonstrated with our patient [1, 11]. An external approach may still be used, either in isolation or in combination with an endoscopic approach, for mucoceles that are difficult to access endoscopically or that require excision of other lesions [7]. Proper management of mucoceles extending into the orbit requires careful coordination between otolaryngologists and ophthalmologists. With prompt care, resolution of ocular symptoms can be achieved with relatively low rates of complication or recurrence.

Acknowledgement

The authors would like to thank the patient for allowing the writing of this report regarding their case.

Statement of Ethics

All research was conducted ethically in accordance with the World Medical Association Declaration of Helsinki. Collection and evaluation of protected patient health information was HIPAA compliant and written consent for medical photographs and their publication was obtained from the patient.

Disclosure Statement

The authors have no conflicts of interest to declare. The authors alone are responsible for the content and writing of the paper.

Funding Sources

No financial support was provided for this case report.

Author Contributions

M.Y.L. Ting acquired, analysed, and interpreted the data, and wrote the paper with support from M. Shan and O. Gantz. S. Zhang-Nunes and B. Wrobel conceived the design and idea of the project, as well as supervised the project. All authors provided input to the drafting and critical revising of the manuscript. All authors agree to be accountable for all aspects of the work.

References

- 1 Lee TJ, Li SP, Fu CH, Huang CC, Chang PH, Chen YW, et al. Extensive paranasal sinus mucoceles: a 15-year review of 82 cases. *Am J Otolaryngol*. 2009 Jul-Aug;30(4):234–8.
- 2 Obeso S, Llorente JL, Pablo Rodrigo J, Sánchez R, Mancebo G, Suárez C. [Paranasal sinuses mucoceles. Our experience in 72 patients]. *Acta Otorrinolaringol Esp*. 2009 Sep-Oct;60(5):332–9. Spanish.
- 3 Iannetti G, Cascone P, Valentini V, Agrillo A. Paranasal sinus mucocele: diagnosis and treatment. *J Craniofac Surg*. 1997 Sep;8(5):391–8.
- 4 Iliff CE. Mucoceles in the orbit. *Arch Ophthalmol*. 1973 May;89(5):392–5.
- 5 Pool JL, Potanos JN, Krueger EG. Osteomas and mucoceles of the frontal paranasal sinuses. *J Neurosurg*. 1962 Feb;19(2):130–5.
- 6 Fokkens W, Jones N. Management of the frontal sinus. In: Flint P, editor. *Cummings Otolaryngology*. 6th ed. Philadelphia: Elsevier Saunders; 2015. pp. 790–802.

- 7 Conboy PJ, Jones NS. The place of endoscopic sinus surgery in the treatment of paranasal sinus mucocoeles. *Clin Otolaryngol Allied Sci.* 2003 Jun;28(3):207–10.
- 8 Hejazi N, Witzmann A, Hassler W. Ocular manifestations of sphenoid mucocoeles: clinical features and neurosurgical management of three cases and review of the literature. *Surg Neurol.* 2001 Nov;56(5):338–43.
- 9 Capra GG, Carbone PN, Mullin DP. Paranasal sinus mucocoele. *Head Neck Pathol.* 2012 Sep;6(3):369–72.
- 10 Loo JL, Looi AL, Seah LL. Visual outcomes in patients with paranasal mucocoeles. *Ophthal Plast Reconstr Surg.* 2009 Mar-Apr;25(2):126–9.
- 11 Kim YS, Kim K, Lee JG, Yoon JH, Kim CH. Paranasal sinus mucocoeles with ophthalmologic manifestations: a 17-year review of 96 cases. *Am J Rhinol Allergy.* 2011 Jul-Aug;25(4):272–5.
- 12 Lund VJ. Endoscopic management of paranasal sinus mucocoeles. *J Laryngol Otol.* 1998 Jan;112(1):36–40.

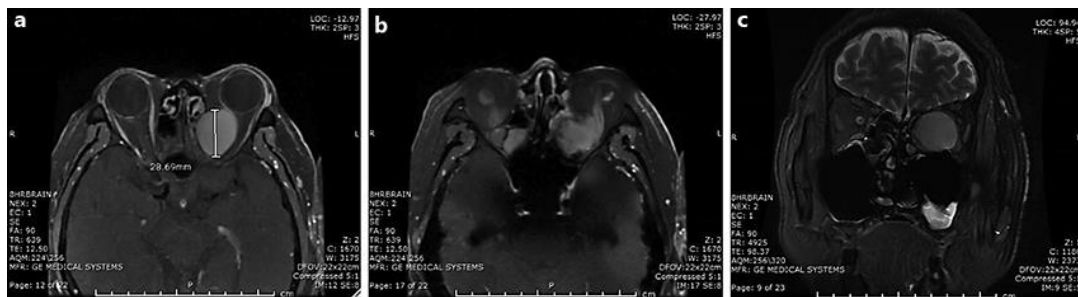


Fig. 1. **a** MRI orbit/face/neck T1 FS axial section, post-contrast. There was a 2.8 × 2.6 × 2.3 cm expansile lesion in the left posterior ethmoid sinus, with intrinsic T1 hyperintensity but no abnormal enhancement, most consistent with a mucocele. It extended laterally into the left orbital apex, presenting as mass effect on and causing lateral deviation of the optic nerve. Furthermore, there was deviation of the medial and inferior recti, and abutment of the superior oblique and superior rectus. **b** There was a smaller 1.7 × 1.5 × 1.2 cm posterior ethmoid mucocele found on the right side. **c** MRI T2 FS coronal section. Mucocele at its largest dimension, causing compression of the optic nerve.

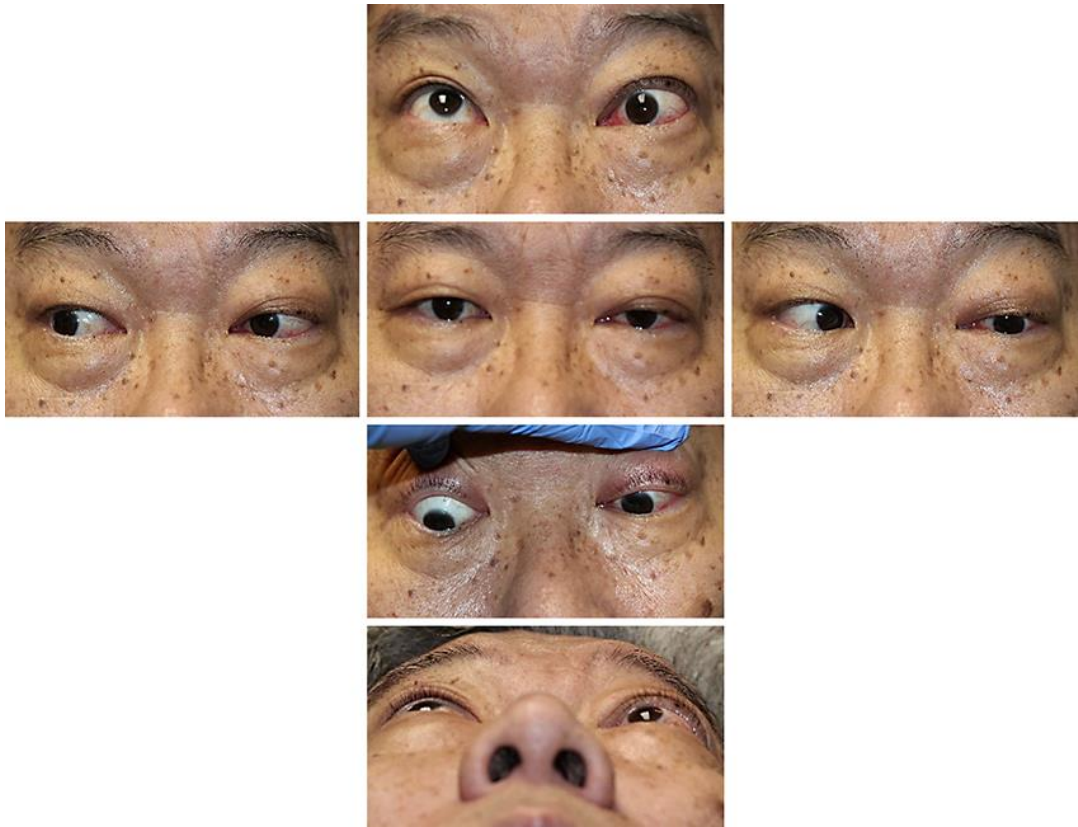

Fig. 2. Pre-operative photos showing left-sided proptosis, conjunctival hyperaemia, and lateral gaze palsy.

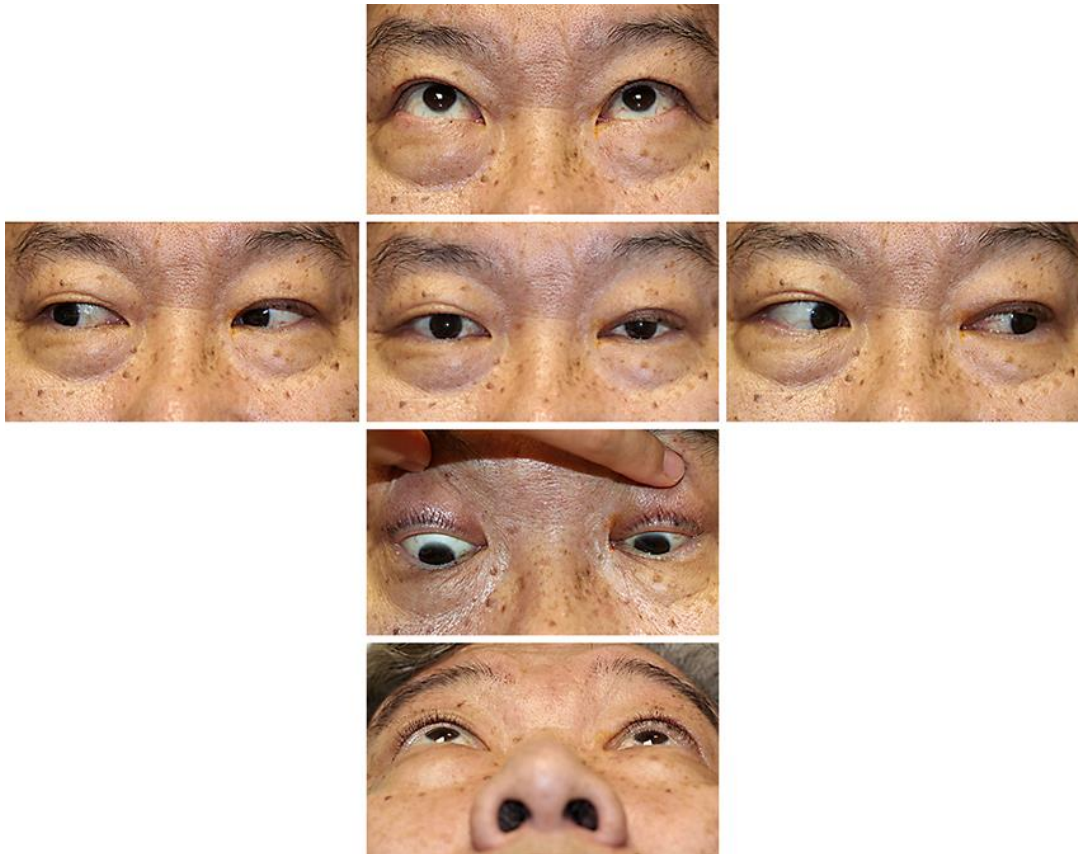

Fig. 3. Post-operative photos on day 13 showing persistence of good extraocular motility, with slight left-sided ptosis and resolution of proptosis.

Table 1. Results from our literature review on the percentage of patients/mucoceles presenting with visual loss

Papers	Total patients/ mucoceles, <i>n</i>	Presenting with visual loss, <i>n</i>
Lee [1], 2009	82	20
Obeso [2], 2009	72	1
Iannetti [3], 1997	53	32
Iliff [4], 1973	6	0
Pool [5], 1961	18	4
Conboy [7], 2003	68	1
Hejazi [8], 2001	3	3
Capra [9], 2012	1	1
Loo [10], 2008	10	4
Kim [11], 2011	96	18
Lund [12], 1998	48	9
Total	457	93 (20.35%)