

MR Imaging-Based Assessment of Carotid Atheroma- A Comparative Study of Patients with and without Coronary Artery Disease

Authors:

Ammara Usman MD, MBA¹

Umar Sadat MD, PhD²

Zhongzhao Teng PhD¹

Martin J Graves, PhD¹

Jonathan R Boyle MD, FRCS²

Kevin Varty MD, FRCS²

Paul D Hayes MD, FRCS²

Jonathan H Gillard MD, MBA, FRCP, FRCR¹

¹University Department of Radiology, Cambridge University Hospitals NHS Foundation Trust, Cambridge, United Kingdom

²Cambridge Vascular Unit, Cambridge University Hospitals NHS Foundation Trust, Cambridge, United Kingdom

Running title: Carotid MR Imaging

Word count: 1574

Abstract word count: 224

Key words: MRI, Carotid, Coronary Artery Disease, Black blood imaging, Functional imaging

Corresponding author:

Dr. Ammara Usman

Box 218, Level 5,

University Department of Radiology,

Addenbrooke's Hospital,

Cambridge Biomedical Campus,

Hills Road, Cambridge, CB2 0QQ

Phone No: 01223 245151,

E-mail: au239@cam.ac.uk

Conflict of interests: None

Abstract:

Background:

Functional magnetic resonance (MR) imaging of atheroma using contrast media (CM) enables assessment of the systemic severity of atherosclerosis in different arterial beds. Whether black blood imaging has similar ability remains widely unexplored. In this study we evaluate whether black blood imaging can differentiate carotid plaques of patients with and without coronary artery disease (CAD) in terms of morphological and biomechanical features of plaque vulnerability, thereby allowing assessment of systemic severity nature of atherosclerosis in different arterial beds.

Methods:

Forty one patients with CAD and fifty nine patients without CAD underwent carotid black blood MR imaging. Plaque components were segmented to identify large lipid core, ruptured fibrous cap and plaque haemorrhage. These segmented contours of plaque components were used to quantify maximum structural biomechanical stress.

Results:

Patients with CAD and without CAD had comparable demographics and co-morbidities. Both groups had comparable prevalence of morphological features of plaque vulnerability [fibrous cap rupture 44% vs. 41%, $p=0.90$; plaque hemorrhage 58% vs. 47%, $p=0.78$; large lipid core 32% vs. 47%, $p=0.17$] respectively. The maximum biomechanical stress was not significantly different for both groups [241 vs. 278kPa, $p=0.14$] respectively.

Conclusions:

Black blood imaging does not appear to have the ability to differentiate between morphological and biomechanical features of plaque vulnerability when comparing patients with and without symptomatic atherosclerotic disease in a distant arterial territory such as coronary artery.

Introduction:

Carotid atherosclerosis is a predominant cause of ischaemic cerebrovascular events. Due to the systemic nature of atherosclerotic disease process, more than one arterial bed may be affected simultaneously (1). Plaque burden in one arterial bed (such as carotid) can predict the severity of atherosclerotic disease burden in a distant territory (such as coronary); and also clinically predict future cardiovascular events (2 (3). Functional magnetic resonance (MR) imaging of atheroma using contrast media (CM) such as ultrasmall superparamagnetic particles of iron oxide (USPIO) has been used effectively to demonstrate the systemic inflammatory nature of atherosclerosis. Carotid plaques of patients with symptomatic carotid artery disease have greater inflammatory burden than the asymptomatic contralateral side carotid plaques (4). The carotid plaque inflammatory burden of the latter is greater than those with truly asymptomatic carotid artery disease (5). Patients with symptomatic coronary artery disease (CAD) but having truly asymptomatic carotid artery disease have greater carotid inflammatory plaque burden than those without coronary artery disease (6).

Functional assessment of atheroma requires administration of CM. Black blood MR imaging however enables identification of high-risk plaque features such as fibrous cap rupture and plaque haemorrhage etc without the need for CM (7). It also enables assessment of biomechanical structural stresses within atheroma (8), which have been observed to have strong association with subsequent cerebrovascular ischaemic events (9). Based on the above, carotid plaques of patients with symptomatic and asymptomatic carotid artery disease can be differentiated (8), (10). Whether black blood carotid imaging enables differentiation of carotid plaques of patients with and without CAD, thereby allowing assessment of systemic severity nature of atherosclerosis in different arterial beds; remains predominantly unexplored. In this

manuscript we assess and compare the morphological features of atheromatous carotid plaques of patients with and without CAD. Biomechanical structural stresses of the two patient cohorts are also compared.

Methods:

One hundred consecutive patients with duplex confirmed carotid artery disease were recruited for this study. Of these 41 patients were diagnosed with CAD and 59 without CAD. CAD was diagnosed according to American Heart Association guidelines by a consultant physician in a hospital setting (11). All these patients underwent high resolution carotid MR imaging. Approval from institutional ethics committee was obtained for this project. All patients gave written informed consent before recruitment.

Inclusion and exclusion criteria comprised of the patients with internal carotid artery stenosis from 30-99% on duplex ultrasound imaging and adequate MR image quality to identify the lumen wall and outer boundary of the arterial wall (10). Patients with previous carotid endarterectomy, cardiac arrhythmias, coagulation disorders, undergoing thrombolysis, cardiac pacemaker or metal implants were excluded from the study.

MR Acquisition

High-resolution carotid MR imaging of the research participants was conducted in a 1.5 T MR imaging system (SignaHDx GE Healthcare, Waukesia, WI, USA) which consist of four-channel phased-array neck coil (PACC, Machnet BV, Elde, the Netherlands). Movement artifact was minimized using a dedicated vacuum-based head restraint system (VAC-LOK Cushion,

Oncology Systems Ltd, UK) to maintain the head and neck in a comfortable position and aids in close approximation of the surface coils. After an initial coronal localizer sequence, axial two-dimensional (2D) time-of-flight (TOF) MR angiography was carried out to identify the location of the carotid bifurcation and the stenosis on either side. Axial images were sliced 3mm apart through the common carotid artery following the carotid bifurcation to the extent that stenosis can be identified on the TOF sequence and the whole carotid plaque could be imaged.

The following electrocardiography (ECG)-gated fast spin echo pulse sequences were used to delineate various plaque components such as fibrous cap (FC), lipid content and plaque haemorrhage (PH): T1 weighted (repetition time/ echo time: 1 x RR 7.8 m/s) with fat saturation, proton density (PD) weighted (repetition time/echo time: 2 x RR 7.8 m/s) with fat saturation, T2 weighted (repetition time/echo time: 2 x RR 85 m/s) with fat saturation; and short tau inversion recovery (STIR) (repetition time/ echo time/inversion time: 2 x RR 42 m/s 150 m/s). The field of view was 10 x 10 cm and matrix size 256 x 256. The in-plane spatial resolution achieved was of the order of 0.39 x 0.39 mm.

Image analysis and computation of biomechanical stresses

The degree of luminal stenosis was assessed according to the European Carotid Surgery Trial (ECST) criteria. Plaque components were assessed using criteria previously published in detail¹¹, using plaque segmentation software CMR Tools (London). As previously described, FC disruption was defined as the presence of FC discontinuity and cavity formation in the plaque¹¹. The plaque component areas (mm²) were determined using a previously published method¹¹, and used for volumetric quantification of plaque components (12). A plaque was considered to have

large lipid content if it occupied more than 25% of the total plaque volume (13). Biomechanical stresses were calculated as described (9) (Figure 1). Maximum principle structural stress of each MR slice within a plaque was initially calculated. The maximum of all these values was taken to represent the ‘maximum structural stress’ (M-C Stress) of a plaque.

Statistical analysis

Continuous variables are presented as median (interquartile range-IQR). Data normality was assessed by Shapiro-Wilk’s test. Unpaired t-tests were used for comparison of continuous variables with normal distribution. For variables with non normal distribution, Mann Whitney U test was used. Chi-square test was used for comparison of categorical variables. P-values <0.05 were defined as statistically significant.

Results:

100 patients (34 females; 66 males); (41 CAD and 59 Non-CAD) were included in the study. Patient demographics and co-morbidities for the two patient groups are tabulated (Table 1). Morphological features suggestive of high risk atheroma such as FC rupture, PH and large LC were comparable for the two groups (Table 2). Biomechanical stresses for both groups also did not show any significant difference.

Discussion:

This study shows that patients with known CAD have morphological plaque features which are comparable to those of patients without CAD. Plaque structural stress analysis also suggests comparable results for the two groups.

Functional MR imaging techniques which comprise of USPIO-enhanced imaging (14); and dynamic contrast-enhanced imaging (15) have been used to assess the systemic severity of atherosclerosis by highlighting underlying inflammatory activity. Inflammation is one of the key determinants in the progression and severity of the atherosclerotic process with macrophages as the main cellular mediators in the inflammatory process. Black blood MR imaging of atheroma however allows static image acquisition of morphological plaque features suggestive of plaque vulnerability such as FC rupture, large LC and presence of PH, without use of CM. These high risk features of plaque vulnerability have strong association with the subsequent cerebrovascular events (12). These features also help us to differentiate between patients with acutely symptomatic, recently symptomatic and asymptomatic carotid artery disease¹⁰.

Whether black blood MR imaging has similar ability in investigating and determining the systemic severity of atherosclerosis in various arterial beds in terms of above mentioned morphological features of plaque vulnerability remains unexplored. In this observational study it was seen that morphological features of high risk carotid atheroma did not differ significantly between the patient with and without CAD. This observation is in contrast to our group's previous experience in which USPIO enhanced functional MR imaging showed higher inflammatory burden in carotid atheroma in patients with coronary artery disease as compared to

those without (6). This observation may indicate the limitation of black blood MR imaging to differentiate the systemic severity of atherosclerosis in various patient groups.

Black blood imaging has also been used to assess biomechanical plaque stresses. As the carotid plaque is located at a dynamic position i.e. usually at carotid artery bifurcation, the structural biomechanical forces acting on plaque cannot be overlooked. High biomechanical structural stresses have significant association with subsequent cerebrovascular events (9). In this study no significant difference ($p=0.14$) was observed for both the patient groups.

To retrospectively assess the power of the conducted study, with mean biomechanical stresses of the two independent populations of 262 and 319kPa, $\alpha = 0.05$ and $\sigma = 181$, and average sample size of 50 patients per sample; β was estimated at 35% only. To achieve 80% power, sample size has to be 159 patients in each group. Previously from a longitudinal follow up study performed by our group (9), where significant difference between biomechanical stresses of atherosclerotic plaques associated with and without subsequent cerebrovascular events (mean: 425 and 289kPa), $\sigma = 181$, $\beta = 0.80$, $\alpha = 0.05$, the sample size in each group was estimated at 28 patients in each group. Saam et al have also estimated that a sample size of 14 patients in each group for the quantitative MR assessment of plaques would be sufficient for an MR imaging study (16). The above highlights the variability in population means in different patient populations, which influence sample size and power calculation. This has to be borne in mind for planning future MR imaging studies.

Conclusion:

Though black blood imaging provides a good insight into plaque characterization but it seems to have the limitation of assessing the systemic severity of atherosclerosis. Functional imaging has been observed previously to be superior to the black blood imaging in assessing the systemic severity of atherosclerosis.

Acknowledgements:

AU is funded by Mountbatten Cambridge International Scholarship in collaboration with Cambridge Trust, Christ's college and Sir Ernest Cassel Education Trust. This study was supported by NIHR biomedical research centre. US was funded by Royal College of Surgeons of England/ Medical Research Council (UK) clinical research training fellowship at the time when study was conducted.

References:

1. Fernandez-Friera L, Penalvo JL, Fernandez-Ortiz A, *et al.* Prevalence, Vascular Distribution, and Multiterritorial Extent of Subclinical Atherosclerosis in a Middle-Aged Cohort: The PESA (Progression of Early Subclinical Atherosclerosis) Study. *Circulation* 2015; 131:2104-13.
2. Sillesen H, Muntendam P, Adourian A, *et al.* Carotid plaque burden as a measure of subclinical atherosclerosis: comparison with other tests for subclinical arterial disease in the High Risk Plaque Biolmage study. *JACC Cardiovasc Imaging* 2012; 5:681-9.
3. Baber U, Mehran R, Sartori S, *et al.* Prevalence, impact, and predictive value of detecting subclinical coronary and carotid atherosclerosis in asymptomatic adults: the Biolmage study. *J Am Coll Cardiol* 2015; 65:1065-74.
4. Tang T, Howarth SP, Miller SR, *et al.* Assessment of inflammatory burden contralateral to the symptomatic carotid stenosis using high-resolution ultrasmall, superparamagnetic iron oxide-enhanced MRI. *Stroke* 2006; 37:2266-70.

5. Tang TY, Howarth SP, Miller SR, *et al.* Comparison of the inflammatory burden of truly asymptomatic carotid atheroma with atherosclerotic plaques contralateral to symptomatic carotid stenosis: an ultra small superparamagnetic iron oxide enhanced magnetic resonance study. *J Neurol Neurosurg Psychiatry* 2007; 78:1337-43.
6. Tang TY, Howarth SP, Miller SR, *et al.* Comparison of the inflammatory burden of truly asymptomatic carotid atheroma with atherosclerotic plaques in patients with asymptomatic carotid stenosis undergoing coronary artery bypass grafting: an ultrasmall superparamagnetic iron oxide enhanced magnetic resonance study. *Eur J Vasc Endovasc Surg* 2008; 35:392-8.
7. Usman A, Sadat U, Graves MJ, Gillard JH. Magnetic resonance imaging of atherothrombotic plaques. *J Clin Neurosci* 2015; 22:1722-6.
8. Sadat U, Teng Z, Young VE, Graves MJ, Gaunt ME, Gillard JH. High-resolution magnetic resonance imaging-based biomechanical stress analysis of carotid atheroma: a comparison of single transient ischaemic attack, recurrent transient ischaemic attacks, non-disabling stroke and asymptomatic patient groups. *Eur J Vasc Endovasc Surg* 2010; 41:83-90.
9. Sadat U, Teng Z, Young VE, *et al.* Association between Biomechanical Structural Stresses of Atherosclerotic Carotid Plaques and Subsequent Ischaemic Cerebrovascular Events - A Longitudinal in Vivo Magnetic Resonance Imaging-based Finite element Study. *Eur J Vasc Endovasc Surg* 2010
10. Sadat U, Weerakkody RA, Bowden DJ, *et al.* Utility of high resolution MR imaging to assess carotid plaque morphology: A comparison of acute symptomatic, recently symptomatic and asymptomatic patients with carotid artery disease. *Atherosclerosis* 2009:434-9.
11. Fihn SD, Blankenship JC, Alexander KP, *et al.* 2014 ACC/AHA/AATS/PCNA/SCAI/STS focused update of the guideline for the diagnosis and management of patients with stable ischemic heart disease: a report of the American College of Cardiology/American Heart Association Task Force on Practice Guidelines, and the American Association for Thoracic Surgery, Preventive Cardiovascular Nurses Association, Society for Cardiovascular Angiography and Interventions, and Society of Thoracic Surgeons. *Circulation* 2014; 130:1749-67.
12. Sadat U, Teng Z, Young VE, Graves MJ, Gillard JH. Three-dimensional volumetric analysis of atherosclerotic plaques: a magnetic resonance imaging-based study of patients with moderate stenosis carotid artery disease. *Int J Cardiovasc Imaging* 2010; 26:897-904.
13. U-King-Im JM, Tang TY, Patterson A, *et al.* Characterisation of carotid atheroma in symptomatic and asymptomatic patients using high-resolution MRI. *J Neurol Neurosurg Psychiatry* 2008:905-12.
14. Tang TY, Muller KH, Graves MJ, *et al.* Iron oxide particles for atheroma imaging. *Arteriosclerosis, thrombosis, and vascular biology* 2009; 29:1001-8.
15. Chen H, Wu T, Kerwin WS, Yuan C. Atherosclerotic plaque inflammation quantification using dynamic contrast-enhanced (DCE) MRI. *Quant Imaging Med Surg* 2013; 3:298-301.
16. Saam T, Kerwin WS, Chu B, *et al.* Sample size calculation for clinical trials using magnetic resonance imaging for the quantitative assessment of carotid atherosclerosis. *J Cardiovasc Magn Reson* 2005; 7:799-808.

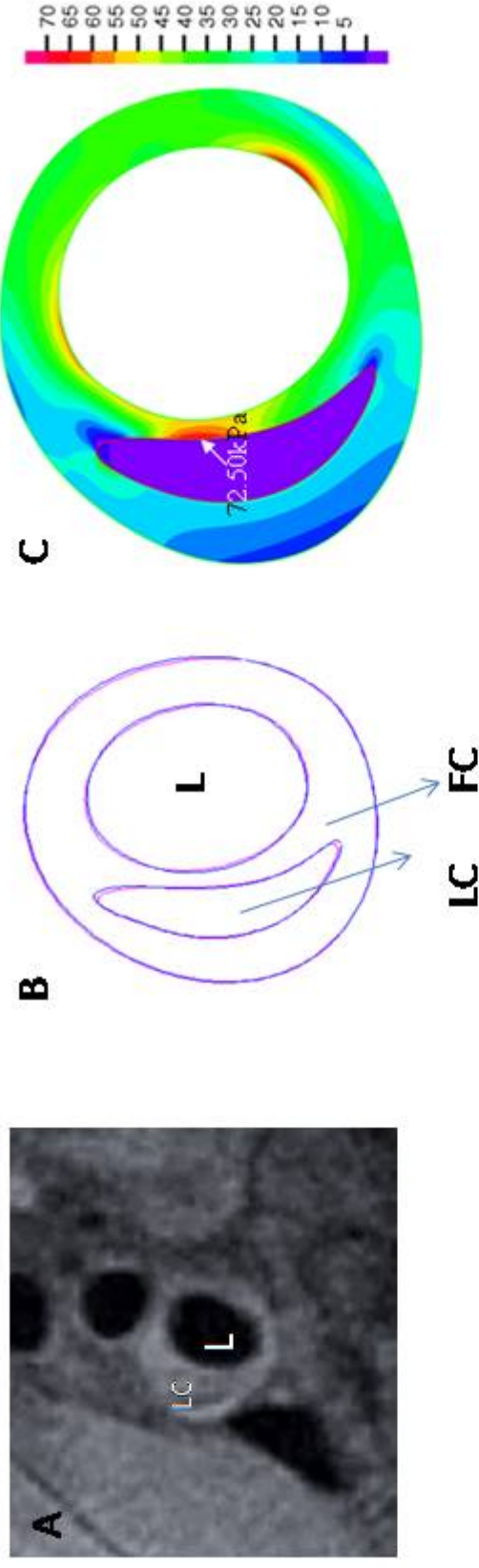


FIGURE 1: (A)shows cross sectional MR black blood image of carotid atheroma with lumen(L) and lipid core (LC). (B) shows contours of the plaque components to be used for biomechanical stress simulation. (C) Finite element analysis showing maximum critical stress (MC-Stress) in kPa at thinnest fibrous cap site.

Table 1: Demographics and co-morbidities of patients with and without coronary artery disease (CAD)

	CAD n= 41	Non-CAD n = 59	p-value
Age*	77 (72-80)	70 (58-80)	0.43
Gender	16F	18F	0.51
Previous transient ischaemic attacks (TIA)	15 (36%)	23 (39%)	0.97
TIA	13 (32%)	20 (34%)	0.98
Non-disabling stroke	6 (15%)	13 (22%)	0.51
Hypercholesterolemia	13 (32%)	20 (34%)	0.98
Hypertension	34 (83%)	47 (79%)	0.88
Diabetes	5 (12%)	7 (12%)	0.96
Chronic obstructive pulmonary disease	1(3%)	0 (0%)	0.85
Renal impairment	3 (7%)	6 (12%)	0.89
Peripheral vascular disease	7 (17%)	7 (12%)	0.65
Coronary artery bypass grafting	17 (42%)	0 (0%)	0.0001
Coronary angioplasty	8 (19%)	0 (0%)	0.001
Aspirin before admission	32(78%)	27 (46%)	0.01
Luminal stenosis*	50 (42-58)	49 (45-60)	0.76

*Continuous variables expressed as median with interquartile range.

Table 2: Comparison of the high-risk plaque features in patients with and without CAD

	CAD n= 41	Non-CAD n = 59	p-value
Fibrous cap rupture	18 (44%)	24 (41%)	0.90
Plaque hemorrhage	24(58%)	28(47%)	0.78
Large lipid core	13(32%)	28(47%)	0.17
M-C Stress (kPa)	241 (176-360)	278 (195-370)	0.14