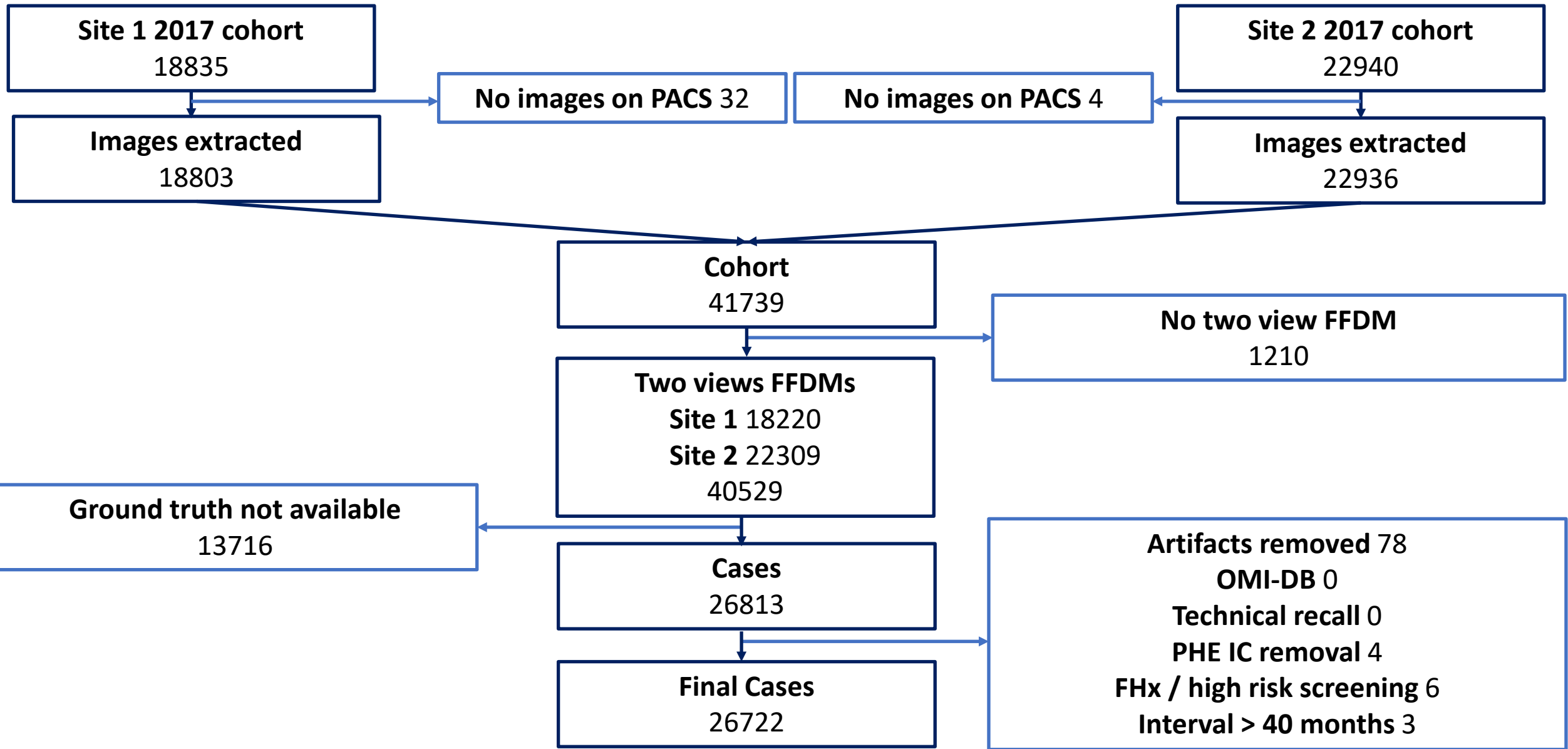
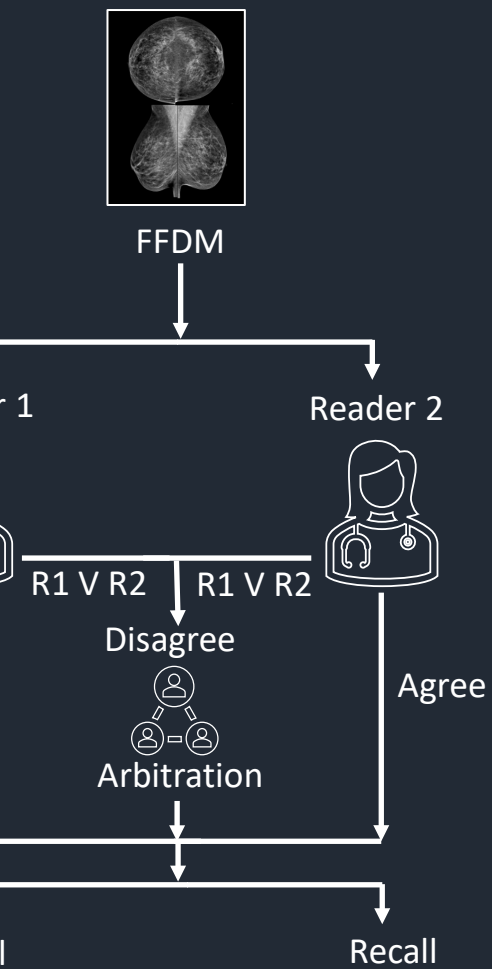


Paper 2

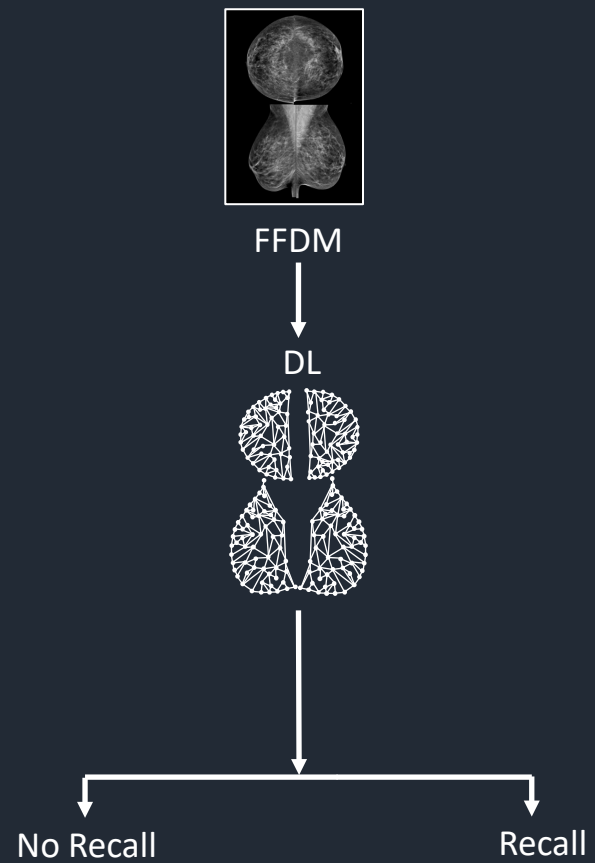
10.07.23



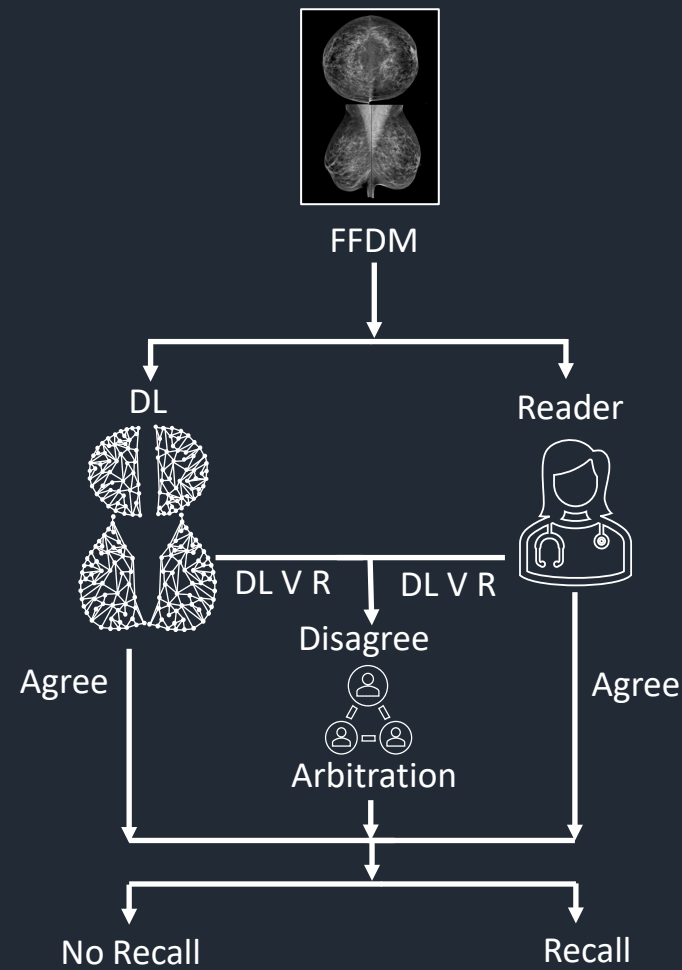
Routine Double Reading

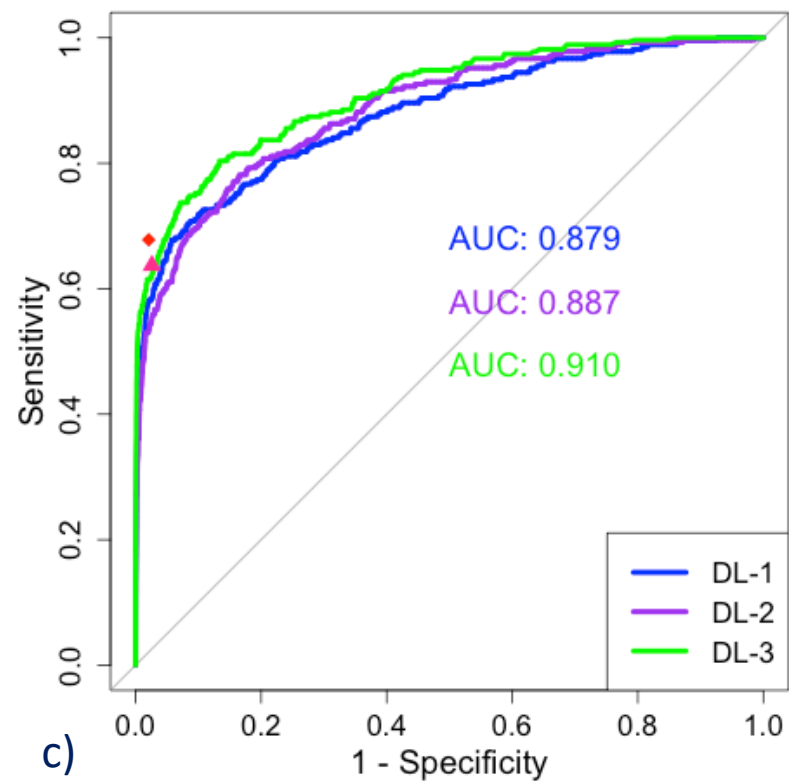
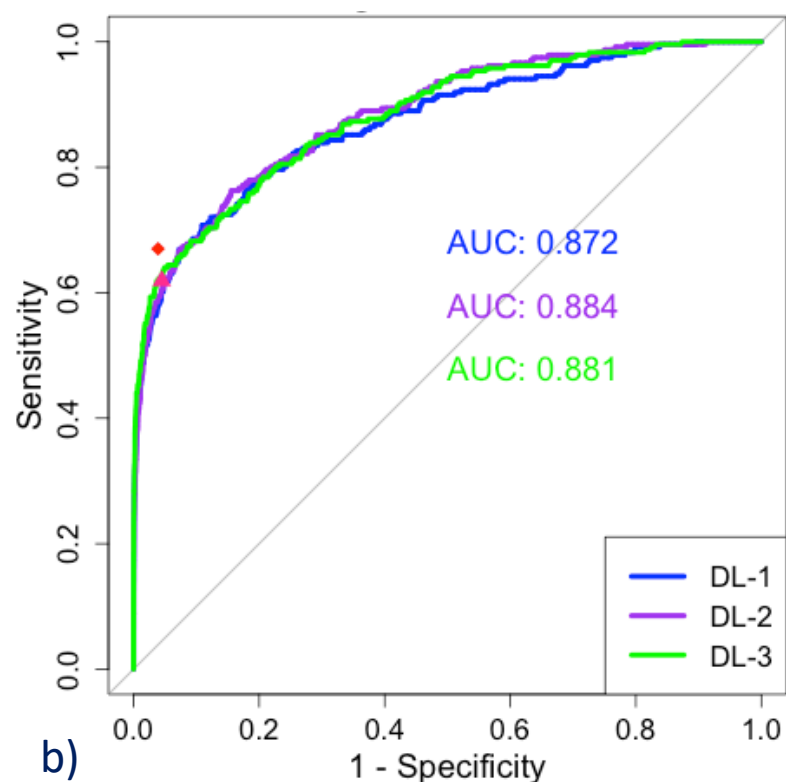
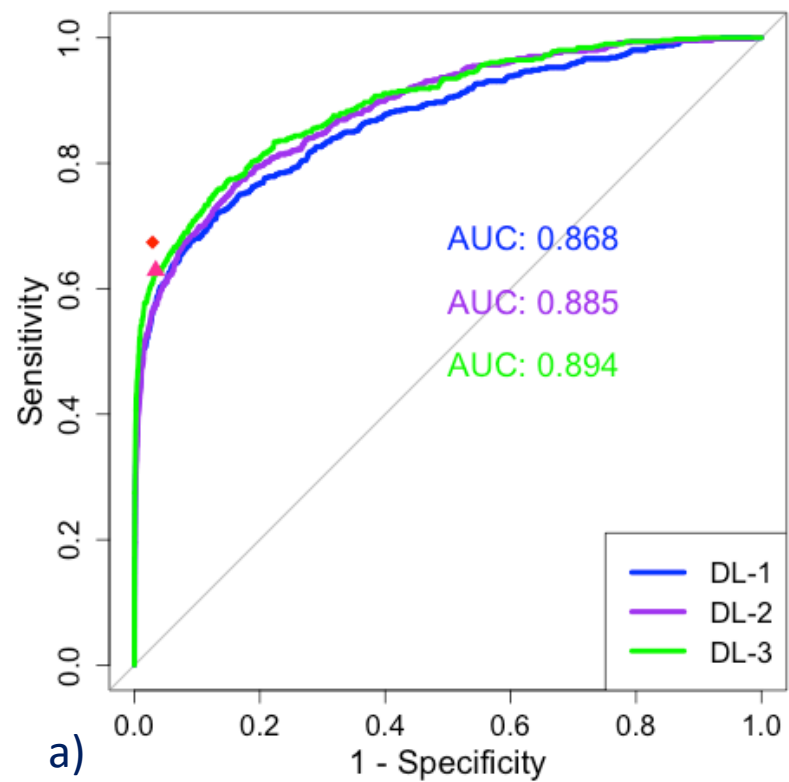


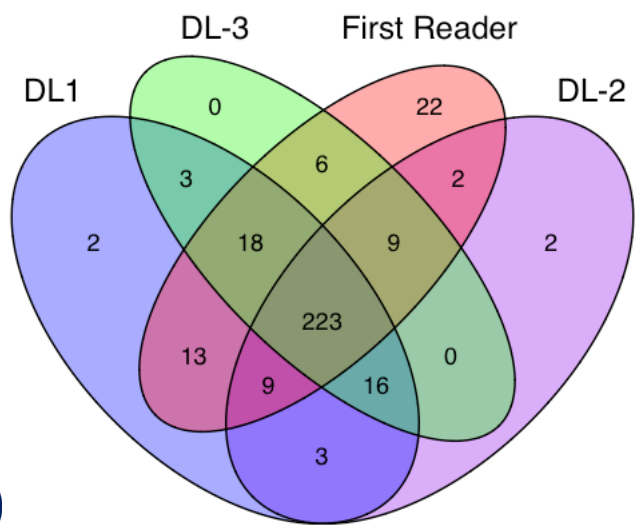
Scenario A



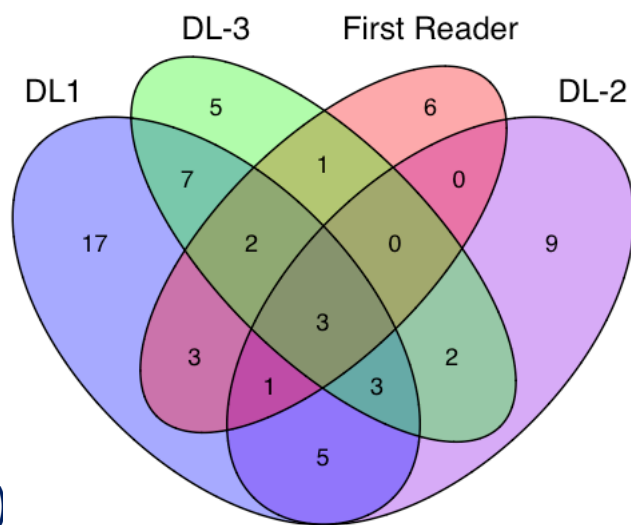
Scenario B



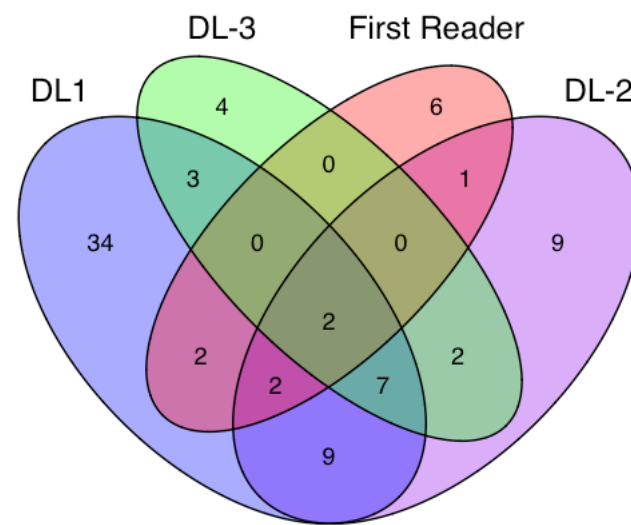




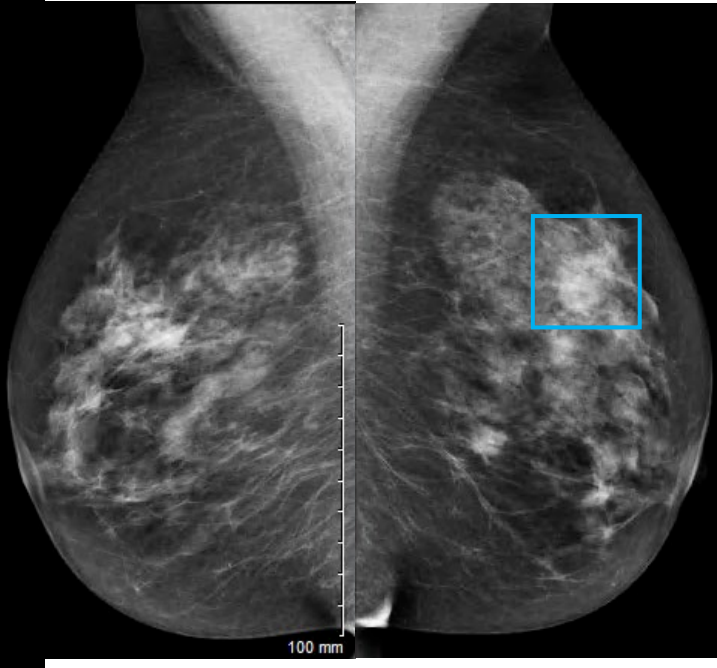
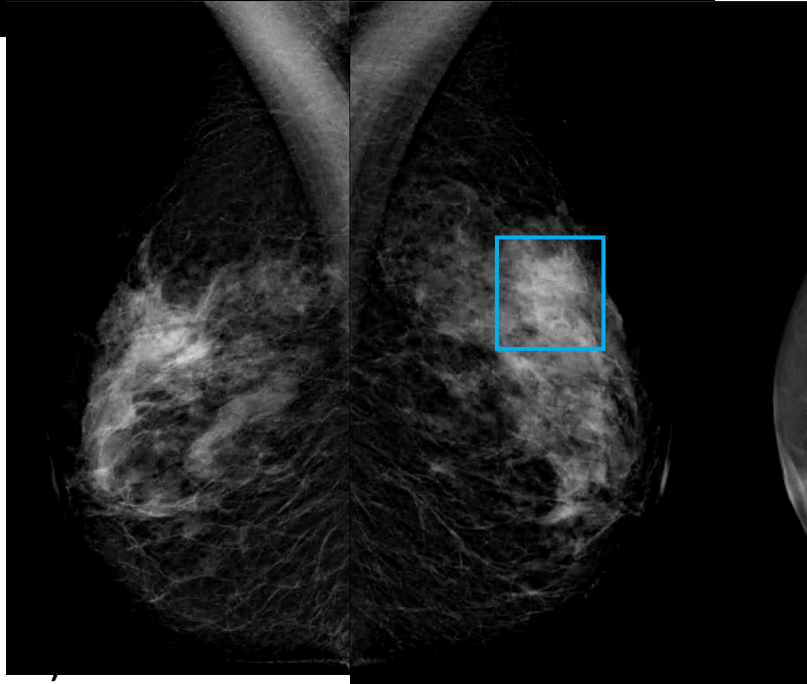
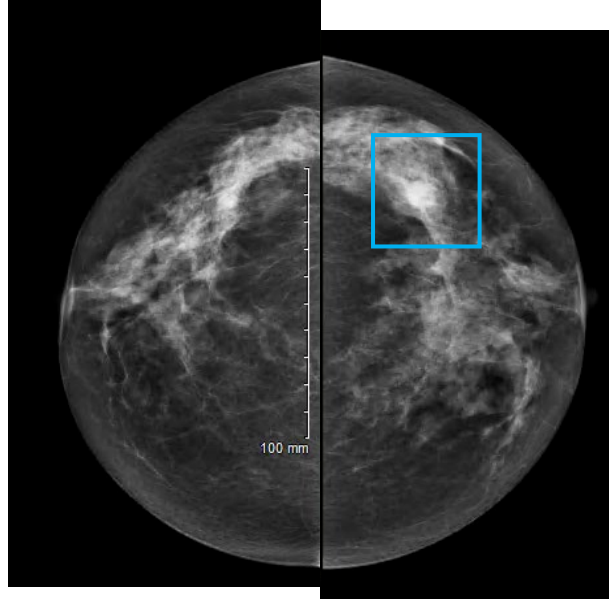
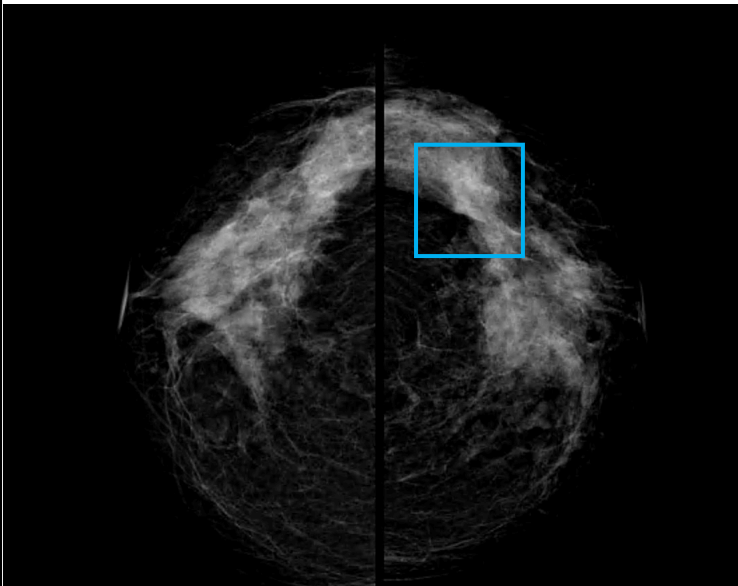
a)



b)



c)



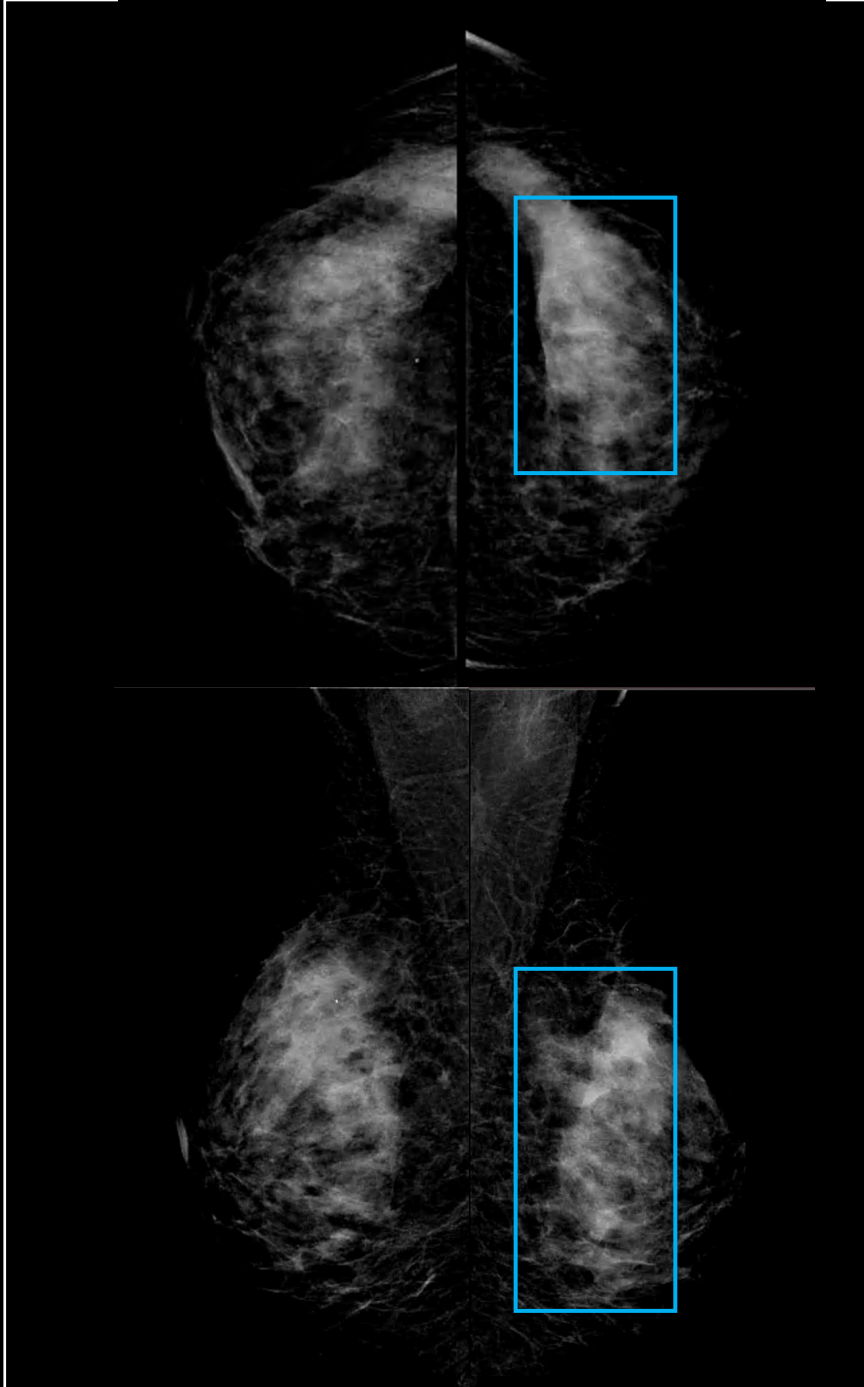
CC06-009734-2
Uncertain
Age 57
Left
691 days
G2
15mm
Invasive
Missed by all

Description

- *Figure 5 – Failure case analysis, of case missed by both deep learning (DL) and human readers. a) Screening image b) diagnostic image, with a blue bounding box to show the location of the cancer. The screen and diagnostic images were annotated by a breast radiologist to show the true location of the cancer.*
- *Interval cancer patient age 57 years old, who was diagnosed old 691 days after screening with a 15mm invasive grade 2 cancer in the left breast.*

Example:

Patient 63 years old recalled to assessment for abnormality in the upper outer quadrant. a) MLO & CC screening mammogram shows ill-defined irregular mass (arrow) b) DBT of the left breast confirms 8 mm irregular mass in the upper outer quadrant with some associated distortion, c) Ultrasound - left upper outer breast just above the nipple there is a 8 mm ill-defined hypoechoic mass, taller than wide, interrupting breast architecture (arrow), d) MRI left breast demonstrating an irregular mass at the level of the nipple just lateral to the midline which measures 10 mm x 7 mm x 10 mm and has a type 1 curve. Histopathology - 16 mm invasive lobular carcinoma, Grade 2, ER 8, PR 6, HER2 negative.



CC06-058389-2

Screen detected

Age 51

Left

G3

3mm – Invasive

107 – non-invasive

Missed by AI

Description

- *Figure 6 – Failure case analysis, case missed by all deep learning (DL) algorithms. a) Screening image, with a blue bounding box to show the location of the cancer. The screen images were annotated by a breast radiologist to show the true location of the cancer.*
- *Screen detected cancer patient age 51 years old, who was diagnosed with a 3mm invasive grade 3 cancer in the left breast.*