

# Case 267

Marcin Czarniecki, MD • Tristan Barrett, MD • Nikesh Thiruchelvam, MD • Oliver Wiseman, MD

From the Departments of Radiology (M.C., T.B.) and Urology (N.T., O.W.), Addenbrooke's Hospital and the University of Cambridge, Cambridge, England. Received January 13, 2017; revision requested February 14; revision received February 20; accepted March 9; final version accepted April 12. **Address correspondence to** M.C., Department of Radiology, MedStar Georgetown University Hospital, 3800 Reservoir Rd NW, Washington, DC 20007 (e-mail: [marcin.b.czarniecki@gunet.georgetown.edu](mailto:marcin.b.czarniecki@gunet.georgetown.edu)).

Conflicts of interest are listed at the end of this article.

Radiology 2019; 290:839–842 • <https://doi.org/10.1148/radiol.2019162780> • Content code: **GU** • ©RSNA, 2019

**History** A 28-year-old man presented with lifelong anejaculation, which had become an issue because of family planning. The patient had a history of normal erections and experienced the sensation of orgasm without ever ejaculating. On physical examination, both testes were present in the scrotum, with normal dimensions and a normal epididymis bilaterally. The patient had a slightly tender left testicle, and digital rectal examination findings were normal.

The patient underwent further investigation for the possibility of retrograde ejaculation with urine cytology, the results of which were negative. Genetic testing was performed to exclude Y chromosome microdeletions. Serum-luteinizing and follicle-stimulating hormone levels were normal, with a borderline low level of testosterone (7.6 nmol/L; normal range, 8.0–29.0 nmol/L). All other pertinent laboratory results were noncontributory.

Pelvic MRI was requested to exclude an anatomic cause of anejaculation. MRI was performed in accordance with the standard clinical prostate protocol, with a dynamic contrast material—enhanced study (Figs 1–3). CT of the upper abdomen was also performed (Fig 4). The patient subsequently underwent cystoscopy, which revealed an intravesicular fluid-filled mass near the left ureteric orifice (Fig 5).

## 2019 Diagnosis Please Learning Objectives

In submitting a diagnosis for this case, participants demonstrate the ability to

- Recognize normal and abnormal findings as presented in the diagnostic images
- Identify pathologic conditions indicated in the diagnostic images
- Use clinical reasoning skills to generate a list of differential diagnoses

## Accreditation and Designation Statement

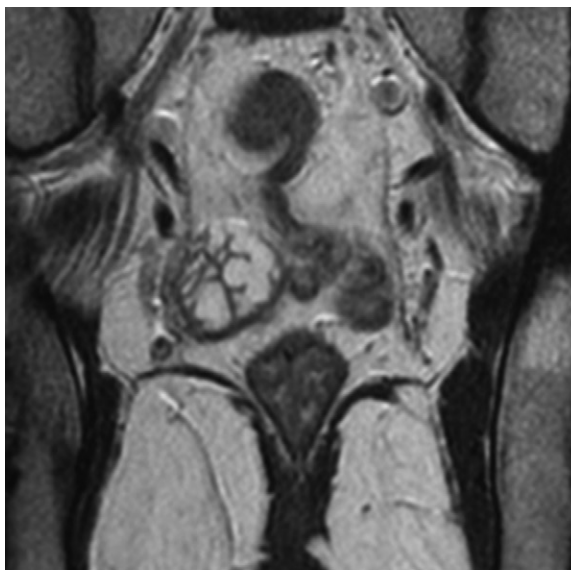The RSNA is accredited by the Accreditation Council for Continuing Medical Education (ACCME) to provide continuing medical education for physicians. The RSNA designates this journal-based CME activity for a maximum of 1.0 *AMA PRA Category 1 Credit*<sup>™</sup>. Physicians should claim only the credit commensurate with the extent of their participation in the activity.

## Disclosure Statement

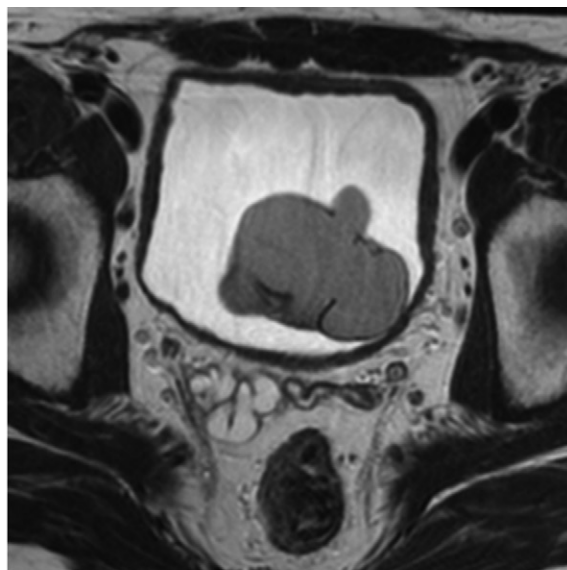
The ACCME requires that the RSNA, as an accredited provider of CME, obtain signed disclosure statements from authors, editors, and reviewers for this case. For this educational activity the authors, editors, and reviewers have indicated that they have no relevant relationships to disclose.

## Submit Diagnosis

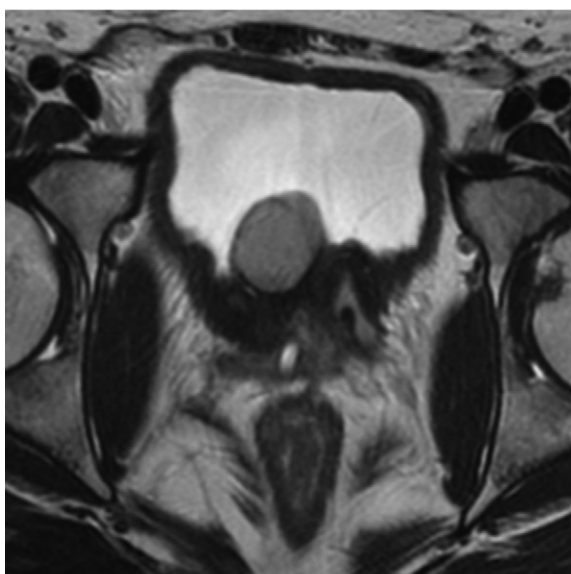
Submit the most likely diagnosis to <http://rsna.org/dx-please> (use only for submission of diagnosis). Select the case from the Active Case List for which you are submitting a diagnosis. Only one case, one name, and one diagnosis per e-mail submission. Multiple diagnoses and multiple submissions will not be considered. **Deadline:** Midnight U.S. Central Time, May 10, 2019. Answer will appear in the July 2019 issue. Authors wishing to submit cases for Diagnosis Please should first write to the Editor to obtain approval for the case and further information.



a.

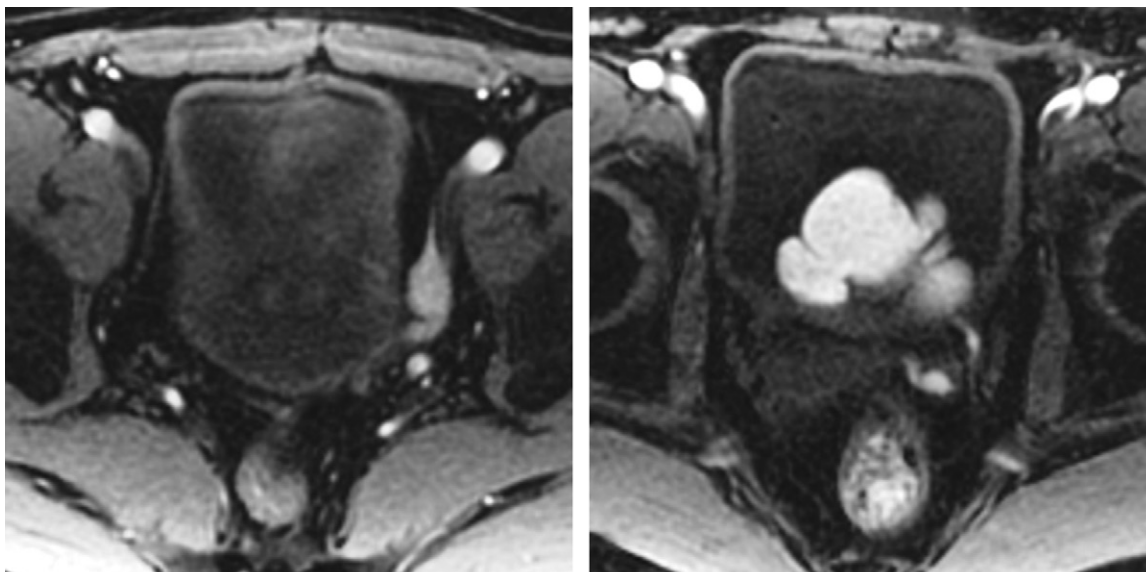


b.



c.

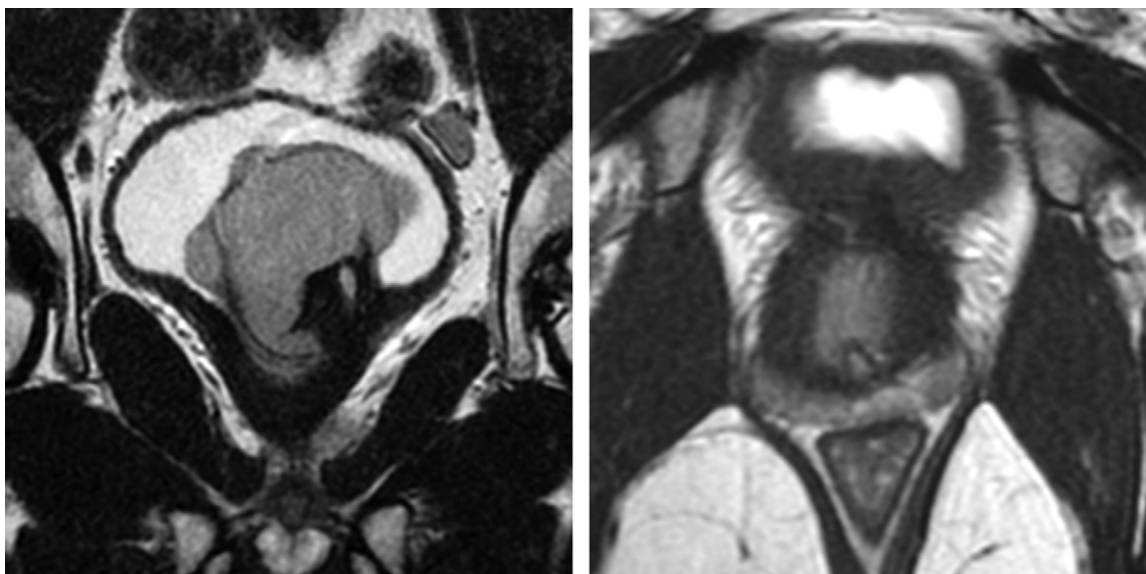
**Figure 1:** (a) Coronal and (b, c) axial fast spin-echo T2-weighted MR images of the pelvis, with b being superior to c.



a.

b.

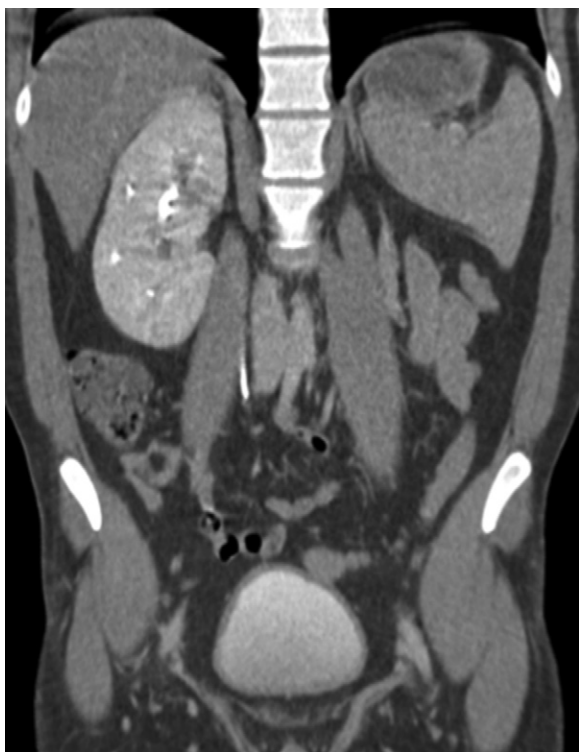**Figure 2:** (a) Coronal T2-weighted (repetition time msec/echo time msec, 4574/86.5) MR image of the pelvis. (b) Axial T2-weighted (3000/85.4) MR image of the pelvis.



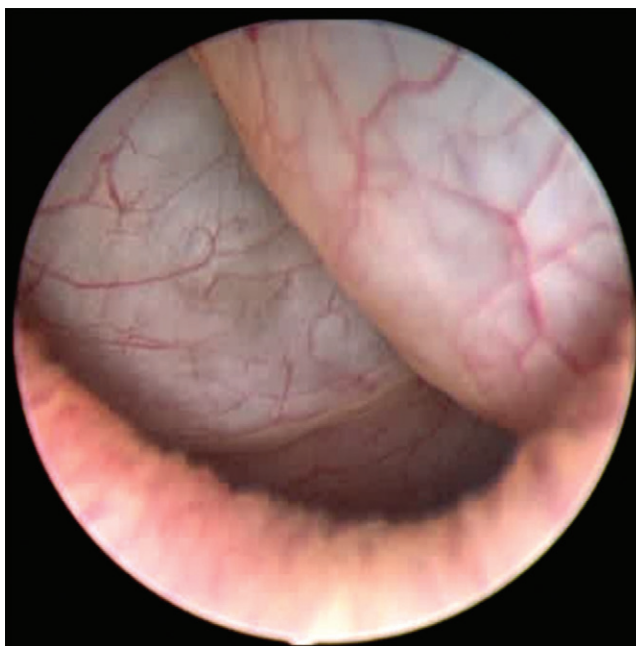
a.

b.

**Figure 3:** Unenhanced axial fatsaturated T1-weighted (6.2/3.1) MR images.



**Figure 4:** Coronal CT urogram.



**Figure 5:** Image obtained at cystoscopy.

**Disclosures of Conflicts of Interest:** M.C. disclosed no relevant relationships. T.B. disclosed no relevant relationships. N.T. Activities related to the present article: disclosed no relevant relationships. Activities not related to the present article: is a consultant to Coloplast and GTU Urological; gave lectures for and was reimbursed for travel expenses by Astellas. Other relationships: disclosed no relevant relationships. O.W. disclosed no relevant relationships.